

Last “Atypical” Beaked Whales Mass Stranding in the Canary Islands (July, 2004)

A Fernández^{1*}, E. Sierra¹, V. Martín², M. Méndez¹, S. Sacchinni¹, Y. Bernaldo de Quirós¹, M. Andrada¹, M. Rivero¹, O. Quesada¹, M. Tejedor² and Arbelo M¹

¹Veterinary Histology and Pathology, Institute of Animal Health, Veterinary School, University of Las Palmas de Gran Canaria, Canary Islands, Spain

²Society for the Study of Cetaceans in the Archipelago Canary (SECAC) – Canary Islands, Spain

Abstract

In July 2004, four *Ziphius cavirostris* stranded in the Canary Islands several days after an international naval exercises were conducted north of the Canary Islands. During the maneuvers high intensity mid-frequency sonar was used. Three of the animals were fully necropsied. Abundant fresh non-digestive aliment was found in all stomachs. Hemorrhages were a constant finding in several organs. Although “*in vivo*” gas embolism could not be established due to decomposition, systemic fat embolism was diagnosed in all three beaked whales. Epidemiological and pathological findings were highly consistent with an “atypical” beaked whale mass stranding that was temporally and spatially associated with sonar. This was the last atypical mass stranding in the Canary Islands once an anti-sonar moratorium was established around the islands, following the EU parliament recommendation and Spanish government resolution in 2004.

Introduction

The possibility that exposure to sonar stimuli could lead to the stranding of cetaceans is an issue of environmental concern because of cetacean stranding and deaths temporally and geographically coincident with naval sonar operations [1,2]. Beaked whales (BWs) (family *Ziphiidae*), one of the deepest-diving whales, are of particular interest because of a notable relationship between military operations employing mid-frequency sonar and BW mass stranding [1,2].

Canary Islands have been a place where more atypical mass stranding associated with naval maneuvers have occurred before 2004 [1,3,4]. Some common epidemiologic factors in this type of mass stranding were: (1) the oceanographic features were characteristic of steep-slope regions; (2) the species involved were predominantly BWs; and (3) these events were temporally associated with naval maneuvers that employed high intensity, low- or mid frequency range sonar signals [3,5].

Fourteen BWs were stranded in the Canary Islands close to the site of an international naval exercise (Neo-Tapon 2002) held on 24 September 2002. A detailed pathological study revealed unusual “bubble” lesions and fat emboli in most of the necropsied beaked whales. These findings constituted a new pathological entity in marine mammals consistent with decompression sickness in human divers [6,7] and was most likely due to a severe changes in the dive behavior of these deep divers [3,6-8]. Epidemiological features, pathological studies, gas analysis and naval exercises information are considered the main diagnostic parameters to approach a diagnosis of this type of atypical mass stranding [3,4,7,9].

Here we report the last beaked whale mass stranding occurred in the Canary Islands in July 2004, associated with naval exercises and antisubmarine sonar activities before an anti-sonar moratorium was recommended by European Union parliament and established around the islands by the Spanish and Canary Islands governments in 2004 [10,11].

Material and Methods

A military international naval exercises (MEDSHARK/Majestic Eagle ‘04 - MS/ME04) involving many warships, aircraft and submarines

from ten allied countries took place north of Canary Islands from 11th through 15th July (2004).

Information about the maneuvers indicated that several warships used mid-frequency sonar (between 2-10 kHz) during the naval maneuvers (Figure 1). Sonar was used in different areas and days to the north of Fuerteventura and Lanzarote islands at 70 nm (on the 11th and 12th July), 85 nm (13th), 60 nm (14th and 15th of July) and at 240 nm on the 16th of July (MEDSHARK/Majestic Eagle ‘04 - MS/ME04).

Four beaked whales (*Z. cavirostris*) were found either floating close to or stranded on Lanzarote and Fuerteventura (the two closest islands to the exercises area) in a six days period from 21st until 26th July (Figure 1). Apart from the last carcass found, all three stranded whales were necropsied [7] and sampled for histological studies as well for microbiological analyses. Samples consisted of skin and fat, skeletal muscle, lung, liver, spleen, lymph nodes and kidney. Other organs were too decomposed for being analyzed.

Results

A 525 cm long male beaked whale (*Z. cavirostris*) showing good body condition and several postmortem shark bites was the first whale to be found on 21st of July in (Los Ancones, 29° 00’ 53” N; 13° 28’ 21” W) Lanzarote Island. The animal showed a code 3 (advanced autolysis). Necropsy showed emphysematous lung lobules and hemorrhages in different digestive organs including acoustic fat. Kidney presented parasites (*Crassicauda spp.*), and the stomach contained abundant partially digested squids.

*Corresponding author: A Fernández, Veterinary Histology and Pathology, Institute of Animal Health, Veterinary School, University of Las Palmas de Gran Canaria, Canary Islands, Spain, E-mail: afernandez@dmor.ulpgc.es

Received March 07, 2012; Accepted April 21, 2012; Published April 23, 2012

Citation: Fernández A, Sierra E, Martín V, Méndez M, Sacchinni S, et al. (2012) Last “Atypical” Beaked Whales Mass Stranding in the Canary Islands (July, 2004). J Marine Sci Res Dev 2:107. doi:10.4172/2155-9910.1000107

Copyright: © 2012 Fernández A, et al. This is an open-access article distributed under the terms of the Creative Commons Attribution License, which permits unrestricted use, distribution, and reproduction in any medium, provided the original author and source are credited.

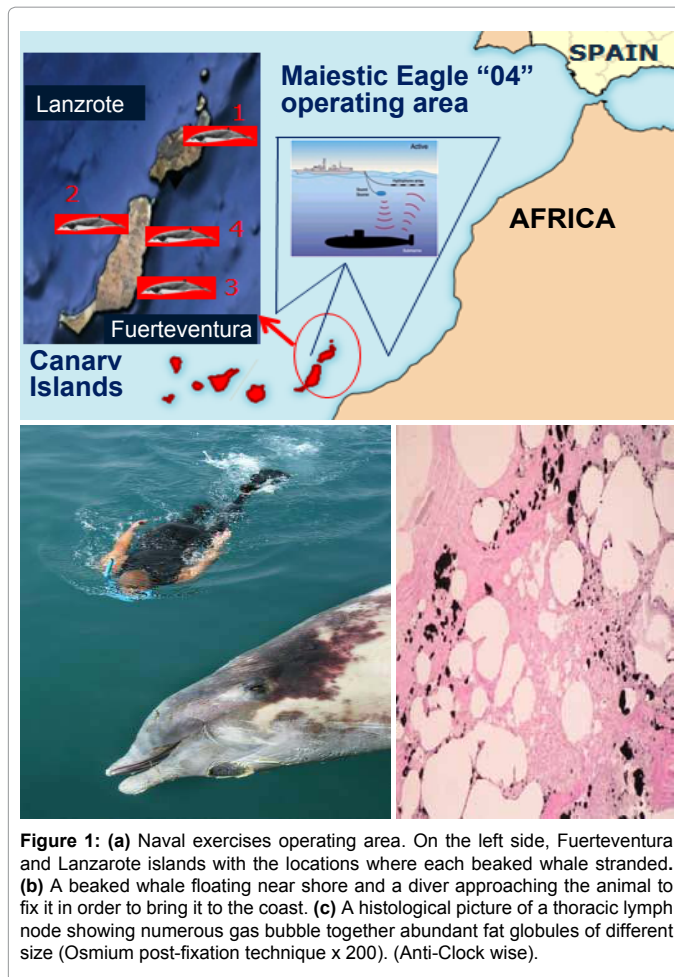


Figure 1: (a) Naval exercises operating area. On the left side, Fuerteventura and Lanzarote islands with the locations where each beaked whale stranded. (b) A beaked whale floating near shore and a diver approaching the animal to fix it in order to bring it to the coast. (c) A histological picture of a thoracic lymph node showing numerous gas bubble together abundant fat globules of different size (Osmium post-fixation technique x 200). (Anti-Clock wise).

On the 23rd of July, a 500 cm long female beaked whale was found floating near shore in Fuerteventura Island (Nuevo Horizonte, 28° 24' 48" N; 13° 50' 53" W). The cetacean presented a good nutritive condition in an advanced autolytic status (code 4). The animal presented no caudal fin with several shark bites in the abdominal area as well as in the melon. During necropsy, abundant fresh undigested food (cephalopods and crustaceans) was present within the stomach compartments. Numerous parasites (*Crassicauda spp.*) were identified in the kidneys, and multiple calcified and fibrotic nodules were identified in the mesenteric arteries. The liver was very flaccid with enlarged venous vessels. Lung lobules were very emphysematous with gas-filled bullae, very likely due to postmortem autolysis. Hemorrhages were observed in the mandibular acoustic fat.

On the 24th of July, a 575 long male *Z. cavirostris* was found stranded in Fuerteventura Island (Majanicho, 28° 44' 21" N; 13° 56' 06" W) a few kilometers away from the previous stranding. Nutritive condition was similar to first beaked whale, and the carcass also showed severe shark bites especially in the abdominal cavity and head. During necropsy, this whale showed similar gross observations as in the previous described whale, including a large quantity of undigested fresh food in the stomach. Part of the digestive and reproductive tract was not present due to shark predation at sea.

Finally, four days later, on the 26th an extremely putrefactive beaked whale of undetermined sex was found beached in Fuerteventura Island (Puerto Lajas, 28° 32' 25" N; 13° 49' 75" W). The carcass was considered

code 5 (advanced decomposition) and therefore too autolysed for necropsy.

Histologically, no inflammatory or neoplastic disease potentially responsible for the cause of death was detected in any organs from the three investigated beaked whales. Emphysematous areas in the lung parenchyma as well as within the lymph nodes were demonstrated histologically. Gas bubbles were microscopically detected within many vessels or tissues, but it was not possible to determine if these were due to putrefaction or some other process. However, using osmium post fixation technique, fat emboli were detected intravascularly in the lungs, kidneys, liver sinusoids and within the lymph nodes in all three stranded whales.

No herpes virus or *Morbillivirus* were detected molecularly by PCR. Isolated enterobacteria from these carcasses were not considered as bacterial postmortem proliferation and no pathogenic ones.

Discussion

Based on the stranding data, this event was defined as an "atypical" beaked whale mass stranding [2], involving *Z. cavirostris*, the most common whale species associated with this kind of stranding. As before it was also temporally and spatially associated with naval activities using high intensity mid-frequency sonar [3,4].

It was suggested that, based on the sea currents during and after the naval exercises, a carcass of that weight would be driven south from the area of the naval exercise to the northern part of the Canary Islands (Lanzarote and Fuerteventura), where these four carcasses eventually beached. This would suggest that beaked whales were originally quite close to the area where naval exercises took place when alive. It would also suggest that the otherwise healthy BWs died relatively quickly at sea before stranding dead on the beach or found floating in seawater. This indicates that beaked whale mass mortalities linked to naval sonars may have directly lethal effects without the need for stranding alive on the beach [5].

These three cases also support the observation (Fernandez, personal communication) that *Z. cavirostris* as a species always appear to float when the body is dead in the water, in contrast to other species from the same *Ziphiidae* family, like *M. densirostris* or *M. bidens* which may sink after death. This observation suggests that other some acoustically-impacted BW species may die at sea and subsequently sink, so the real impact of sonar on this family may be under-represented by stranding.

From the pathological point of view, the high amount of "gas bubble" found in the three necropsied whales could not be considered as an evidence of "gas embolism" since all three animals showed an advanced postmortem autolysis and no gas analysis methodology was then available as it is now [9]. However, the evidence of fat emboli in these beaked whales together with the fact that all three died at sea, are highly suggestive that fat emboli was not due to trauma during stranding but was triggered and developed at sea and probably contributing to the whales relatively rapid death. This also shows that fat embolism is an important pathological finding that can still be investigated even in moderate to advanced autolytic stranded cetaceans [7,12].

The results from mortalities occurred in 2002 and before [3,7] and the results present here provide scientific support for a non-binding EU parliament resolution in 2004 ([<http://www.nrdc.org/media/pressreleases/050210b.asp>] and [<http://www.nrdc.org/media/docs/050210a.pdf>]) on the deployment of high intensity sonars until a global assessment of its cumulative environmental impacts on whales, dolphins, fish and other marine life is completed [10].

Following this resolution the Spanish parliament decided to establish a sonar moratorium around the Canary Islands [11] as a preventive measure to avoid these whales to be affected during naval exercises, mainly in Fuerteventura coasts (Canary Islands). After seven years of this moratorium (2004), we can now present here the last beaked whale mass stranding linked to naval exercises with sonar activities in the Canary Islands occurred in July 2004. No military sonar activities has been deployed since then and no new atypical beaked whales mass stranding has occurred in the Canary Islands from 2004 until 2011. This undoubtedly represents the best supportive evidence for the EU parliament resolution [10] and Spanish moratorium [11] in 2004 when the last mass stranding occurred in the Canary Islands.

Acknowledgment

This work was supported by the Spanish Ministry of Science and Innovation with two research projects: (AGL 2005-07947), and (CGL 2009/12663), as well as the Government of Canary Islands, project, SolSub C200801000288. Cabildo de Fuerteventura (Antonio Gallardo) and Reserva de la Biosfera de Fuerteventura.

References

1. Simmonds MP, Lopezjurado LF (1991) Whales and the military. *Nature* 351: 448.
2. Frantzis A (1998) Does acoustic testing strand whales? *Nature* 392: 29.
3. Cox TM, Ragen TJ, Read AJ, Vose E, Baird RW, et al. (2006) Understanding the impacts of anthropogenic sound on beaked whales. *J Cetacean Res Manage* 7: 117-187.
4. Amico AD, Gisiner RC, Ketten DR, Hammock JA, Johnson C, et al. (2009) Beaked whale strandings and naval exercises. *Aquatic Mammals* 35: 452-472.
5. Evans DL, England GR (2001) Joint Interim Report: Bahamas Marine Mammal Stranding Event of 15-16 March 2000. US Department of Commerce and US Navy: Washington DC.
6. Jepson PD, Arbelo M, Deaville R, Patterson IA, Castro P, et al. (2003) Gas-bubble lesions in stranded cetaceans. *Nature* 425: 575-576.
7. Fernández A, Edwards JF, Rodríguez F, Espinosa de los Monteros A, Herráez P, et al. (2005) "Gas and fat embolic syndrome" involving a mass stranding of beaked whales (family Ziphiidae) exposed to anthropogenic sonar signals. *Vet Pathol* 42: 446-457.
8. Tyack PL, Zimmer WM, Moretti D, Southall BL, Claridge DE, et al. (2011) Beaked whales respond to simulated and actual navy sonar. *PLoS One* 6: e17009.
9. de Quirós YB, González-Díaz O, Saavedra P, Arbelo M, Sierra E, et al. (2011) Methodology for in situ gas sampling, transport and laboratory analysis of gases from stranded cetaceans. *Sci Rep* 1: 193.
10. European-Parliament (2004) European Parliament resolution on the environment effects of high-intensity naval sonars.
11. Daily sessions of the Congress of Deputies. Cdl Deputies, Editor 2004. File Number 180/000 345.
12. Jepson PD, Deaville R, Patterson IA, Pocknell AM, Ross HM, et al. (2005) Acute and chronic gas bubble lesions in cetaceans stranded in the United Kingdom. *Vet Pathol* 42: 291-305.

Submit your next manuscript and get advantages of OMICS Group submissions

Unique features:

- User friendly/feasible website-translation of your paper to 50 world's leading languages
- Audio Version of published paper
- Digital articles to share and explore

Special features:

- 200 Open Access Journals
- 15,000 editorial team
- 21 days rapid review process
- Quality and quick editorial, review and publication processing
- Indexing at PubMed (partial), Scopus, DOAJ, EBSCO, Index Copernicus and Google Scholar etc
- Sharing Option: Social Networking Enabled
- Authors, Reviewers and Editors rewarded with online Scientific Credits
- Better discount for your subsequent articles

Submit your manuscript at: www.editorialmanager.com/envirosci

